

## EP CASE REPORT

# Vagal third-degree atrioventricular block in a highly trained endurance athlete

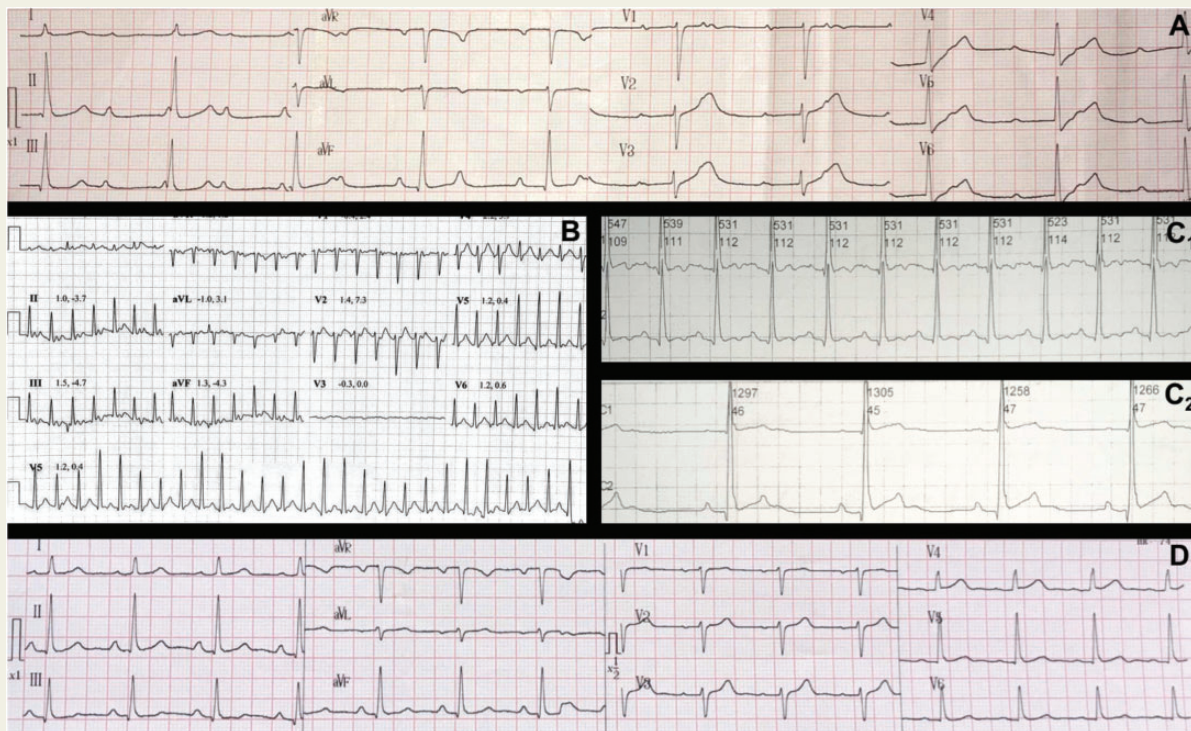
Alejandro Vidal\*, Valentina Agorrody, Rodrigo Abreu, Pablo Viana, Alejandro Dodera, and Luis Vidal

Department of Montevideo, Sanatorio Americano, Isabelino Bosch 2466, Montevideo 11600, Uruguay

\* Corresponding author. Tel: (+598) 27086041. E-mail address: dralejandroidal@gmail.com

The electrocardiogram (ECG) characteristics of athletes have recently become a topic of intensive study to accurately identify dangerous and benign alterations in this special population. These subjects develop a high-vagal tone and consequently sinus bradycardia and different degrees of atrioventricular (AV)-block,<sup>1</sup> but it is difficult to determine how much is too much, and the indications for a pacemaker must be clearly defined, as it could ruin their careers.

A 39-year-old male smoker that performed high-endurance mountain biking (up to 200 km/day, 5 times/week, for the last 3 years) had 45 bpm asymptomatic bradycardia in a routine examination. The ECG showed a sinus rate of 100 bpm with a complete heart block (CHB) and a nodal escape with a narrow QRS of 45 bpm (Panel A). His ECG was normal. The subject was referred to us for possible pacemaker implantation. Cycle ergometry was performed and CHB disappeared as soon as he started to exercise (without a significant change in the sinus rate), initially presenting with second degree AV-block and then becoming first degree AV-block (PR 260 ms). The test was stopped



once the diagnosis was reached with a maximum heart rate of 167 bpm (Panel B) and the performance intensity was around 12 metabolic equivalents. We reassured the subject and suggested deconditioning. No pacemaker was implanted. After mild deconditioning, he continued to be asymptomatic and 6 months later a Holter register showed sinus rhythm with medial, minimum and maximum rates of 75, 45 and 111 bpm, respectively, (Panel C<sub>1</sub>). First degree AV-block was registered during sleep (Panel C<sub>2</sub>) and no second or third degree AV-block was detected. His ECG was normal (Panel D).

It is very rare to see a vagal junctional CHB with a sinus rate of 100 bpm in an athlete. We found only one case in the literature in which no pacemaker was implanted with good results, but the subject had a sinus rate of 70 bpm with a nodal escape at 45 bpm.<sup>2</sup>

We believe that our patient had a localized hyperresponsiveness of the AV node to vagal tone with a relative predominant sympathetic influence at the sinoatrial node—an extreme case of the known inter-individual differences that can develop in both the sinoatrial node and AV node.<sup>1,3</sup> The fact that AV conduction immediately improved without changes in the sinus rate supports our hypothesis that the vagal suppression effects are much faster than sympathetic activation.<sup>1</sup>

High-degree AV-blocks may be diagnosed in athletes and physicians must carefully evaluate them case-by-case to make a correct decision about pacemaker implantation after considering the site of the block, the pathophysiology and the symptoms.

**Conflict of interest:** none declared.

## References

1. Levy MN, Martin PJ. Autonomic neural control of cardiac function. In: N Sperelakis (ed). *Physiology and Pathophysiology of the Heart*. 2nd ed. Boston, MA: Kluwer Academic Publishers; 1989. p361–79.
2. Hernández-Madrid A, Moro C, Huerta Marín E, Rayo I. Third-degree atrioventricular block in an athlete. *J Intern Med* 1991;**229**:375–6.
3. Rubin DA, Nieminski KE, Woolf P, Herman M V. Selective hypervagotonia isolated to the atrioventricular node. *Pacing Clin Electrophysiol* 1988;**11**:1529–32.